

Case Report

A CASE OF PULMONARY TUBERCULOSIS WITH FALSE NEGATIVE QuantiFERON®TB-2G TEST

Etsuko NAKASONE, Naoko MATO, Masayuki NAKAYAMA, Masashi BANDO,
and Yukihiko SUGIYAMA

Abstract A 57-year-old man was admitted to our hospital with a high fever and productive cough. He had a previous history of total gastrectomy and splenectomy at the age of 45 years due to gastric cancer. He also showed severe macrocytic anemia with low vitamin B₁₂, and an infiltrative shadow was found in the right lung on an X-ray. Sputum examination on admission revealed no significant pathogenic bacteria, and an acid-fast stain and a *M.tuberculosis* PCR test were negative. QuantiFERON®TB-2G Test (QFT) was negative on admission. Because pneumococcal antigen in the urine was positive, we initially diagnosed pneumococcal pneumonia and treatment with antibiotics was started. However, symptoms were not resolved with several antibiotics, finally, a thoracoscopic lung biopsy under general anesthesia was performed for a definitive diagnosis. The biopsy showed epithelioid cell granuloma in the alveolar spaces, and the 8 weeks culture of sputum taken on admission revealed *M.tuberculosis*. Finally, a pulmonary tuberculosis was diagnosed and treatment with four drugs of HERZ was begun. We have encountered a case of pulmonary tuberculosis combined with a lobar pneumococcal pneumonia, and negative for QFT. In general, splenectomy is known as a risk factor of pneumococcal infection. And vitamin B₁₂ deficiency due to gastrectomy is one of the risk factors for cellular immunity impairment and was possibly to the false negative QFT and development of TB.

Key words: Pulmonary tuberculosis, Gastrectomy, Splenectomy, QFT, Vitamin B₁₂

Introduction

By the early 1980s, cases of tuberculosis (TB) had decreased and it was believed that the disease was being controlled worldwide¹⁾. However, recently the number of TB cases has been increasing, so an appropriate diagnosis at the initial phase is considered very important in order to avoid the transmission of TB to other people²⁾.

The authors report a case of pulmonary TB, which was initially considered as a bacterial pneumonia, because of a mixed infection with *Streptococcus pneumoniae* (*S.pneumoniae*) and a false-negative QuantiFERON®TB-2G Test (QFT). And we discuss the influence of immune status to develop TB and false-negative QFT in this article.

Case

A 57 year-old man was admitted with a history of fever (39.0°C) and productive cough. He had a previous history of total gastrectomy and splenectomy at the age of 45 years due to gastric cancer, but no history of pneumococcal vaccination. On physical examination, he had conjunctival anemia, and

coarse crackles were heard in the right chest.

Laboratory examination showed an elevated inflammatory response and macrocytic anemia with decreased levels of vitamin B₁₂. Blood gas analysis showed hypoxemia at PaO₂ 61.4 Torr with oxygen administration (2 L/minute). Repeated sputum smear of an acid-fast stain and *M.tuberculosis* PCR were negative, and other significant bacteria were not detected. QFT was negative (Table). The chest X-ray (Fig. 1a) showed infiltrative shadows in the right upper and middle lung field. High-resolution computed tomography (HRCT) scan showed consolidation with air bronchogram in the right upper and middle lobe and patchy infiltrative shadows in the right S⁶ (Fig. 1b). The mediastinal lymph nodes were slightly enlarged.

Urine was positive for pneumococcal capsular antigen on admission, and pneumococcus was assumed to be the pathogen responsible for the right lobar pneumonia. Therefore, antibiotic therapy with ceftriaxone (CTRX) was started. Although the infiltrative shadow showed a slight improvement on the X-ray, his fever persisted. Therefore, the antibiotic was changed, firstly to meropenem (MEPM), and subsequently to

pazfloxacin (PZFX) and tazobactam/piperacillin (TAZ/PIPC). Then, because his clinical and radiological improvement remained poor, bronchial lavage and transbronchial lung biopsy was performed to identify the pathogen. However, as no specific findings were obtained, a surgical lung biopsy was performed from right S³, S⁶, and S⁸ lobes and the subsequent histopathological examination showed multiple epithelioid cell

granulomas (Fig. 2). Furthermore, the 8-week culture of sputum obtained on admission revealed *M.tuberculosis*. According to these findings, the patient was diagnosed with pulmonary TB combined with pneumococcal infection, and combination therapy with isoniazid (INH, 300 mg), rifampicin (RFP, 450 mg), ethambutol (EB, 750 mg), pyrazinamide (PZA, 1,500 mg) was started, as well as vitamin B₁₂ supplements (Fig. 3).

Table Laboratory data on admission

[Blood count]		[Blood chemistry]		[Other]	
WBC	10.5×10 ³ /μl	CRP	10.91 mg/dl	Vitamin B ₁₂	30.0 pg/ml
Neu.	79.0 %	TP	5.4 g/dl	Folate	12.5 ng/ml
Lym.	11.4 %	Alb	2.0 g/dl	Serum iron	15 μg/dl
RBC	123×10 ⁴ /μl	BUN	21 mg/dl	Ferritin	151.7 ng/ml
Hb	6.1 g/dl	Crea	0.52 mg/dl	Mycoplasma antibodies	<40X
Ht	18.6 %	T-Bil	0.36 mg/dl	Chlamydia pneumoniae	
MCV	149 fl	AST	18 mU/ml	IgG	0.34 (-) IgA 1.07 (±)
MCH	49.1 pg	ALT	20 mU/ml	β-D-glucan	<0.5 pg/ml
MCHC	34.1 %	LDH	307 mU/ml	Cryptococcal antigen	(-)
Plt	11.9×10 ⁴ /μl	CPK	37 mU/ml	Aspergillus antigen	(-)
ESR	112 mm/h	Na	137 mmol/l	HIV antibody	(-)
		K	3.7 mmol/l	Pneumococcal antigen in urine	(+)
		Cl	102 mmol/l	Legionella antigen in urine	(-)
		Glu	175 mg/dl	Quantiferon (QFT)	(-)
		IgG	1747 mg/dl	ESAT-6	-0.02 U/ml
		IgA	364 mg/dl	CFP-10	0.01 IU/ml
		IgM	49 mg/dl	Interferon-γ	0.2 pg/ml
				[Sputum examination]	Grade 4
					Smear negative for acid-fast bacilli
					PCR (-) for <i>M.tuberculosis</i>
					No other significant bacteria

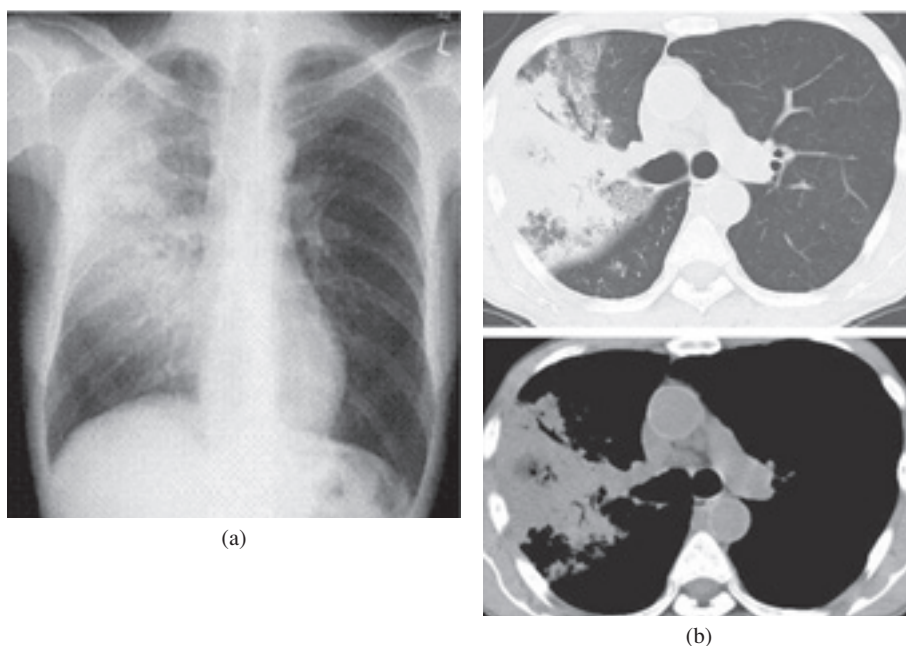


Fig. 1 (a) Chest X-ray film on admission showing infiltrative shadows in the right upper and middle lung fields. (b) HRCT showing consolidation with air bronchogram in the right upper and middle lobes and patchy infiltrative shadows in the right S⁶. The mediastinal lymph nodes are slightly enlarged.

Thereafter, his clinical symptoms and radiological findings gradually improved and serum vitamin B₁₂ levels were normalized.

Discussion

We have reported a case of pulmonary TB developing lobar pneumonia with mixed infection of pneumococci, and QFT showed false negative.

Thus far, only a few cases have been reported of mixed infection by TB and other pathogens; co-infection with *S. pneumoniae*³⁾, *Nocardia*⁴⁾, *S. anginosus*⁵⁾ have all been report-

ed. Simultaneous infection is rare, and occurs mainly in acquired immunodeficiency syndrome³⁾. In our case, we initially underdiagnosed as simple pneumococcal pneumonia because of a positive urine pneumococcal antigen result and of lobar pneumonia pattern on admission. CRP and the infiltrative shadow on the X-ray improved by antibiotic therapy with CTRX. But, his fever persisted. Mixed infection by other pathogens is considered to present a risk for the underdiagnosis of TB, and we should keep this possibility in mind, especially in immunodeficient cases.

Pulmonary TB produces a broad spectrum of radiographic

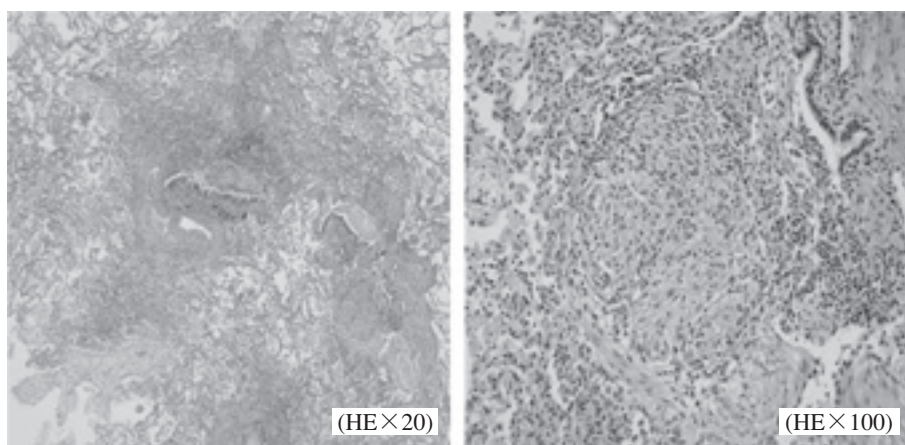


Fig. 2 Tissue section of surgical lung biopsy obtained from right S³ showing epithelioid cell granulomas

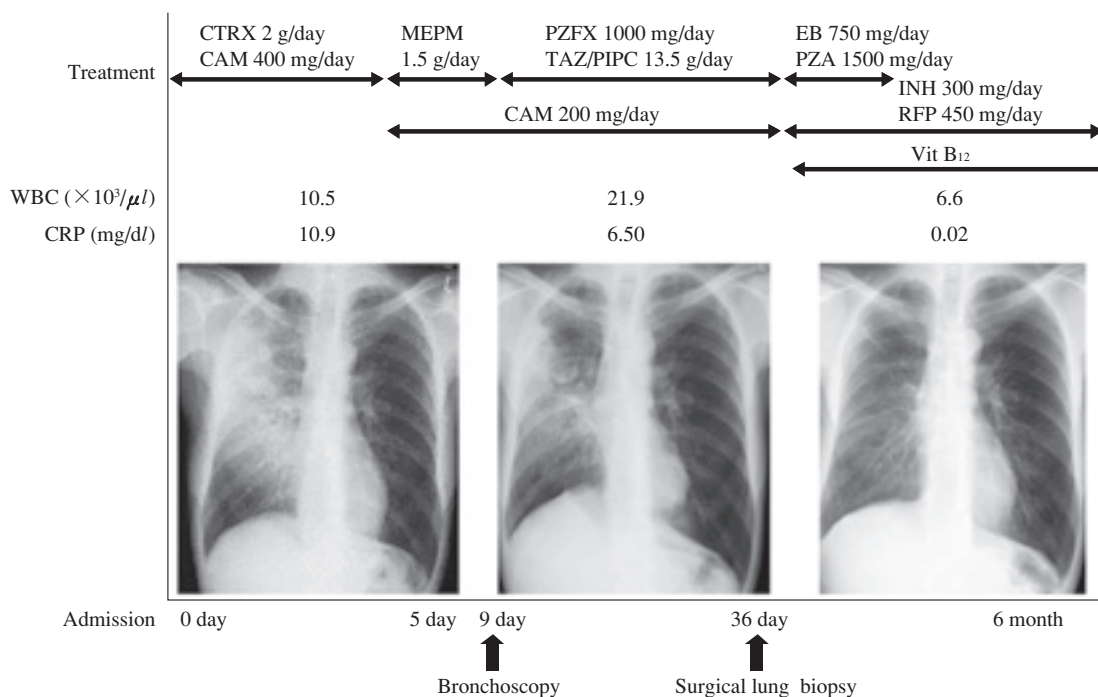


Fig. 3 Clinical course of the patient after admission
 CTRX: ceftriaxone, MEPM: meropenem, PZFX: pazfroxacin, TAZ/PIPC: tazobactam/piperacillin, INH: isoniazid, RFP: rifampicin, EB: ethambutol, PZA: pyrazinamide, CAM: clarithromycin

abnormalities. Generally, heterogeneous parenchymal opacity and cavity are characteristic findings in adult post-primary TB. However, in practice, it is difficult to differentiate from other types of acute pneumonia based on radiological findings. For example, Liam et al. reported that TB was isolated in 4.9% patients initially diagnosed with community-acquired pneumonia⁶⁾, and other authors have also described that TB was identified in quite a high percentage of cases of community-acquired pneumonia⁷⁾⁸⁾.

Furthermore, other studies have shown that radiological findings are greatly affected by the host's immunological state, because impaired host immunity also impaired host-pathogen interaction and led to atypical pathological and radiological findings⁹⁾. Cell-mediated immunity is known to reduce by the following conditions: HIV infection, malnutrition, malignancy, diabetes mellitus and administration of corticosteroid or immunosuppressant¹⁰⁾. In our case, though the patient was not an HIV carrier, he had a history of total gastrectomy due to gastric cancer 12 years ago, and he had not accepted vitamin B₁₂ substitution therapy, and because of this he had macrocytic anemia. Vitamin B₁₂ is involved in folate metabolism as well as thymidine and purine synthesis and plays essential roles in subsequent DNA and RNA synthesis¹¹⁾. Some authors have reported that vitamin B₁₂ deficiency can induce apoptosis, and cause a significant decrease in CD8⁺ T cells¹²⁾¹³⁾, abnormally high CD4⁺/CD8⁺ ratio¹⁴⁾, and suppression of NK cell activity¹⁵⁾. Furthermore, it has been demonstrated that the incidence of TB in vegetarians was high, which associated with vitamin B₁₂ deficiency¹⁶⁾.

Although the positive rate of QFT in TB patients is 88.2%, some authors have reported that its sensitivity can drop to 58–70% in compromised hosts (HIV, steroid and immunosuppressant use, malignant tumors, diabetes mellitus)^{17–19)}. In the present case, we speculate that vitamin B₁₂ deficiency might cause the decrease in the numbers of CD8⁺ T cells and impairment of cellular immunity, and this might lead to the impairment of TB-specific IFN- γ production. That resulted in a false negative QFT.

On the other hand, a wide variety of disorders can result in diminished splenic function. The spleen normally has a protective role against specific infection. In particular, because the spleen filters encapsulated bacteria such as *S.pneumoniae*, asplenic individuals have increased risk of life-threatening overwhelming pneumococcal sepsis²⁰⁾. We speculate that asplenia is one of the critical risk factors leading to the simultaneous *S.pneumoniae* infection in the present case.

In conclusion, we report a case, with histories of total gastrectomy and splenectomy, who developed pulmonary TB with simultaneous bacterial infection. It is important to be aware of the possibility of false negative QFT and bacterial mixed infection in pulmonary TB, especially in immunosuppressive cases.

References

- 1) Van der Brande P, Vanhoenacker F, Demedts M: Tuberculosis at the beginning of the third millennium: one disease, three epidemics. *Eur Radiol.* 2003 ; 13 : 1767–70.
- 2) Curvo-Semedo L, Teixeira L, Caseiro-Aives F: Tuberculosis of the chest. *Eur J Radiol.* 2005 ; 55 : 158–72.
- 3) Schleicher G, Feldman C: Dual infection with *Streptococcus pneumoniae* and *Mycobacterium tuberculosis* in HIV-seropositive patients with community acquired pneumonia. *Int J Tuberc Lung Dis.* 2003 ; 7 : 1207–8.
- 4) Chaudhury RC, Aher AR, Rastogi V, et al.: A case of mixed pulmonary infection by nocardia and *Mycobacterium tuberculosis*. *Indian J Pathol Microbiol.* 2009 ; 52 : 294–5.
- 5) Rabunal R, Corredoira J, Monte R, et al.: Co-infection by *Streptococcus anginosus* and *Mycobacterium tuberculosis*: three case reports. *J Med Case Reports.* 2009 ; 3 : 37.
- 6) Liam CK, Pang YK, Pooaparajah S: Pulmonary tuberculosis presenting as community-acquired pneumonia. *Respirology.* 2006 ; 11 : 786–92.
- 7) Ishida T, Hashimoto T, Arita M, et al.: Etiology of community-acquired pneumonia in hospitalized patients: a 3-year prospective study in Japan. *Chest.* 1998 ; 114 : 1588–93.
- 8) Park DR, Sherbin VL, Goodman MS, et al.: The aetiology of community-acquired pneumonia at an urban public hospital: influence of immunodeficiency virus infection and initial severity of illness. *J Infect Dis.* 2001 ; 84 : 268–77.
- 9) Jeong YJ, Lee KS: Pulmonary tuberculosis: up-to-date imaging and management. *ARJ Am J Roentgenol.* 2008 ; 191 : 834–44.
- 10) Ikezoe J, Takeuchi N, Johkoh T, et al.: CT appearance of pulmonary tuberculosis in diabetic and immunocompromised patients: comparison with patients who had no underlying disease. *AJR.* 1992 ; 159 : 1175–9.
- 11) Maggini S, Wintergerst SE, Beveridge S, et al.: Selected vitamins and trace elements support immune function by strengthening epithelial barriers and cellular and humoral immune responses. *Br J Nutr.* 2007 ; 98 : S29–35.
- 12) Imamura N, Fujimura K, Kuramoto A: Lymphocyte subpopulations in pernicious anemia. *N Engl J Med.* 1984 ; 56 : 311.
- 13) Courtemanche C, Elson-Schwab I, Mashiyama ST, et al.: Folate deficiency inhibits the proliferation of primary human CD8⁺T lymphocytes *in vitro*. *J Immunol.* 2004 ; 173 : 3186–92.
- 14) Kubota K, Kurabayashi H, Kawada E, et al.: Restoration of abnormally high CD4/CD8 ratio and low natural killer cell activity by vitamin B₁₂ therapy in a patient with post-gastrectomy megaloblastic anemia. *Intern Med.* 1992 ; 31 : 125–6.
- 15) Tamura J, Kubota K, Murakami H, et al.: Immunomodulation by vitamin B₁₂: augmentation of CD8⁺T lymphocytes and natural killer cell activity in vitamin B₁₂ deficient patients by methyl-B₁₂ treatment. *Clin Exp Immunol.* 1999 ; 116 : 28–

- 32.
- 16) Chanarin I, Stephenson E: Vegetarian diet and cobalamin deficiency: their association with tuberculosis. *J Clin Pathol.* 1988 ; 41 : 759–62.
- 17) Kobashi Y, Mouri K, Obase Y, et al.: Clinical evaluation of QuantiFERON TB-2G test for immunocompromised patients. *Eur Respir J.* 2007 ; 30 : 945–50.
- 18) Kawabe Y: Application and problems of QuantiFERON® TB-2G for tuberculosis control programs (2) Clinical use of QuantiFERON® TB-2G. *Kekkaku.* 2007 ; 82 : 61–6.
- 19) Ariga H: Applications and challenges of QFT in immunosuppressed individuals. *Kekkaku.* 2009 ; 84 : 333.
- 20) Coignard-Biehler H, Lanternier F, de Montalembert M, et al.: Infections in splenectomized patients. *Rev Prat.* 2008 ; 58 : 2209–14.